



PATIENT

Riel Fecik

SPECIES

Feline

BREED

DMH

SEX

Female Spayed

AGE

6 years

WEIGHT

11.9lbs

INTERPRETED BY

Maggie Machen
 Lamy, DVM, DACVIM
 (Cardiology)

IMAGING PERFORMED BY

Sara Hansen

HOSPITAL NAME

Companion Animal
 Clinic

REFERRING VET

Dr. Castita

INVOICE

30664

DATE

5/8/23

PRESENTING CLINICAL SIGNS

History: Screening exam. Sibling recently died of heart disease. No murmur. BP: 133, 152, 141mmHg.

ECHOCARDIOGRAM FINDINGS

2D, m-mode, color flow and doppler imaging is available. The left ventricular wall is normal in dimension. There is a mildly hyperechoic endocardium consistent with mild fibrosis. The endocardium also appears mildly remodeled. The papillary muscles are normal in size and hyperechoic. The left atrium is normal in size. The right atrium is normal in size. The right ventricle appears normal. The mitral valve is normal in structure and mobility. No obvious valve regurgitation. Blood flow through both the LVOT and RVOT is normal in velocity. No pleural or pericardial effusion seen. No obvious cardiac tumors.

CARDIAC CHART

FELINE CARDIAC PARAMETERS	BODY WEIGHT (kg)	HR (BPM)	IVSd (cm) (Moise, Pipers)	LVIDd (cm) (Moise, Pipers)	LVWd (cm) (Moise, Pipers)	FS (%)	EF (%)
NORMAL PARAMETER	-----	150-240	0.35-0.55	<2 (mean 1.5)	3.5-0.55	35-67	80-100
PATIENT	5.4	NM	0.45	1.53	0.46	58	92
FELINE CARDIAC PARAMETERS	LA/AO (Boon)	LA/AO HEART BASE (Swe) (Abbott)	LA 2D short axis Base view (cm) (Abbott)		LVOT VEL (m/s)	RVOT VEL (m/s)	E max (m/s)
NORMAL	<1.5	<1.3	<1.2		<1.6	<1.3	<0.9
PATIENT	1.1	1.1	1.0		0.8	1.1	NM
<p><i>*Note: All measurements based upon multi-modal images and methods. An average value is reported.</i> Adapted from June Boon, Veterinary Echocardiography, 1998 Abbott J & MacLean H JVIM 2006;20: 111-119, Moise et al. Am J Vet Res 47:1476, 1986. Pipers et al. Am J Vet Res 40:882, 1979.</p>							

INTERPRETATION OF THE FINDINGS & FURTHER RECOMMENDATIONS

Overtly normal cardiac structure and function. The LV wall thickness is normal, and there is no evidence of elevated left atrial pressure or underlying pathology at this time. There is mild remodeling and fibrosis of the left ventricular wall, which is considered likely a normal age-related finding. Given these findings, no medications are indicated.

Even without disease identified here, a familiar history may suggest a predisposition lifelong. Routine screening is recommended.

Anesthetic risk is considered mild. With remodeling and diastolic stiffening, there is an elevated risk for fluid overload in this patient and judicious IV fluid use is recommended. Heart rate stimulating drugs such as atropine, glycopyrrolate or ketamine should be avoided unless medically necessary. Risk for complication with steroid use typically follows LA dilation, which in this case is low. That being said, any cat can experience unexpected signs of intolerance and monitoring of RR/RE is advised particularly in the initiation phase.

Recommend recheck echocardiogram in 1 year to assess for any progressive issues.



PATIENT

Riel Fecik

SPECIES

Feline

BREED

DMH

SEX

Female Spayed

AGE

6 years

WEIGHT

11.9lbs

INTERPRETED BY

Maggie Machen
Lamy, DVM, DACVIM
(Cardiology)

IMAGING PERFORMED BY

Sara Hansen

HOSPITAL NAME

Companion Animal
Clinic

REFERRING VET

Dr. Castita

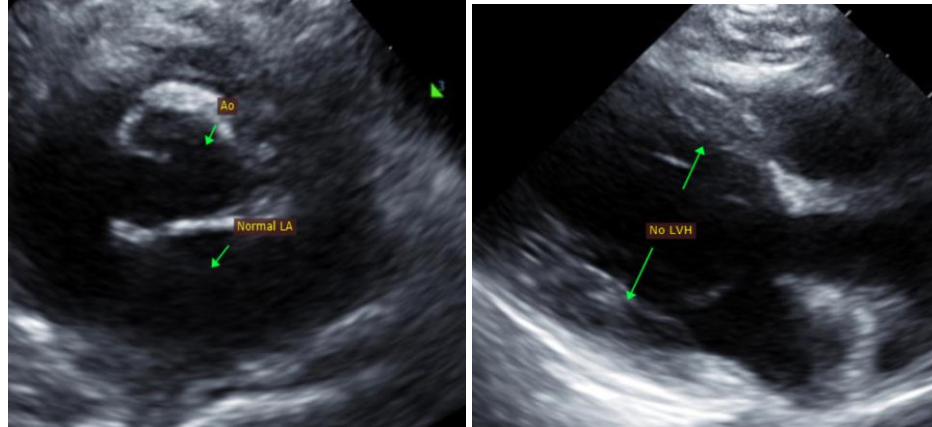
INVOICE

30664

DATE

5/8/23

IMAGES



The information and recommendations provided are based on the images presented by the referring veterinarian. No evaluation can be communicated regarding pathology that was not visible in the image/video clips provided.

Thank you for this referral. This report was generated using transcription software, and minor dictation errors may be present. If the clinical or image interpretation does not parallel your findings or if I can be of any further assistance, please contact me.

Maggie Machen Lamy, DVM
Diplomate of the American College of Veterinary Internal Medicine (Cardiology)
info@sonopath.com